

Breast Reconstruction with the Profunda Artery Perforator Flap

Robert J. Allen, M.D.
 Nicholas T. Haddock, M.D.
 Christina Y. Ahn, M.D.
 Alireza Sadeghi, M.D.
 New York, N.Y.; and New Orleans, La.



Background: The use of perforator flaps has allowed for the transfer of large amounts of soft tissue with decreased morbidity. For breast reconstruction, the deep inferior epigastric perforator flap, the superior and inferior gluteal artery perforator flaps, and the transverse upper gracilis flap are all options. The authors present an alternative source using posterior thigh soft tissue based on profunda artery perforators, termed the profunda artery perforator flap.

Methods: Preoperative imaging helps identify posterior thigh perforators from the profunda femoris artery. These are marked, and an elliptical skin paddle, approximately 27 × 7 cm, is designed 1 cm inferior to the gluteal crease. Dissection proceeds in a suprafascial plane until nearing the perforator, at which point subfascial dissection is performed. The flap has a long pedicle (approximately 7 to 13 cm), which allows more options when performing anastomosis at the recipient site. The long elliptical shape of the flap allows coning of the tissue to form a more natural breast shape.

Results: All profunda artery perforator flaps have been successful. The donor site is well tolerated and scars have been hidden within the gluteal crease. Long-term follow-up is needed to evaluate for possible fat necrosis of the transferred tissue.

Conclusions: The authors present a new technique for breast reconstruction with a series of 27 flaps. This is an excellent option when the abdomen is not available because of the long pedicle, muscle preservation, ability to cone the tissue, and hidden scar. (*Plast. Reconstr. Surg.* 129: 16e, 2012.)

CLINICAL QUESTION/LEVEL OF EVIDENCE: Therapeutic, V.

Perforator flaps allow the transfer of large amounts of soft tissue with decreased morbidity. For breast reconstruction, the deep inferior epigastric perforator flap¹ is the obvious option in most patients; however, in some patients, the thigh or buttock is a good alternative. The common choices are the superior or inferior gluteal artery perforator flaps^{2,3} and the transverse upper gracilis flap.

We present a new option, which uses excess tissue from the posterior thigh. Hurwitz described the use of a posterior thigh myocutaneous flap based on the inferior gluteal artery,⁴ Angrigiani et al. described the transfer of posterior and medial thigh skin based on profunda femoris perforators,⁵ and Song et al. discussed the use of the posterior thigh

perforator free flap.⁶ Cadaver studies have shown that the dominant blood supply to the posterior thigh is from the profunda femoris artery perforators.⁷ Flaps based on this circulation have been routinely used for pressure sores.⁸ We describe the use of the posterior thigh free flap based on profunda artery perforators in a series of 27 breast reconstructions.

Disclosure: *The authors have no financial interest to declare in relation to the content of this article.*

Supplemental digital content is available for this article. A direct URL citation appears in the printed text; simply type the URL address into any Web browser to access this content. A clickable link to the material is provided in the HTML text of this article on the *Journal's* Web site (www.PRSJournal.com).

From the Department of Plastic Surgery, New York University Langone Medical Center, and the Division of Plastic Surgery, Louisiana State University Health Sciences Center.

Received for publication December 17, 2010; accepted June 7, 2011.

Copyright ©2011 by the American Society of Plastic Surgeons

DOI: 10.1097/PRS.0b013e3182363d9f

PATIENTS AND METHODS

Indications

The ideal patient has a breast of small to moderate size, and excess tissue in the posterior thigh. In our experience, suitable patients have had a wide spectrum of body mass indexes, with varying weights and heights. All of our patients have had previous abdominal surgery, limiting abdominal donor tissue, or have been very thin, with limited abdominal tissue. Patients with limited hip abduction are not ideal, as intraoperative positioning is much more difficult if the supine approach is used. Preoperative imaging can identify suitable posterior thigh profunda artery perforators.

Anatomy

The posterior thigh tissue is bordered by the iliotibial tract and adductor muscles horizontally and the gluteal fold and popliteal fossa vertically. The profunda femoris artery enters the posterior compartment of the thigh and typically gives off three main perforators. The first perforator supplies the adductor magnus and gracilis, and the second and third perforators supply the semimembranosus, biceps femoris, and vastus lateralis.⁷

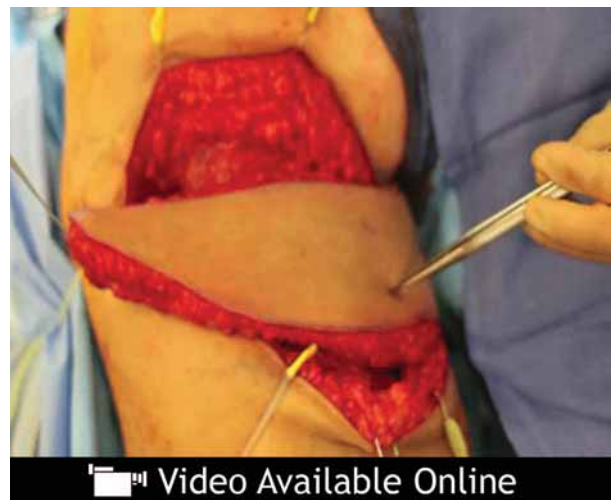Preoperative Imaging and Markings

Magnetic resonance or computed tomographic angiography of the pelvis and thigh with contrast is performed in the planned operative position. Based on the imaging and a handheld Doppler probe, the skin perforators are identified and marked. There are typically both medial and lateral perforators, but we have recently favored the medial perforators. This preference is related to the increased ease of harvest in the supine position and the perforator size. This medial perforator tends to enter posterior to the gracilis muscle. There have been some situations in which a more posterior and lateral perforator was dominant and therefore used. The superior marking is 1 cm inferior to the gluteal fold. The inferior marking is approximately 7 cm below the superior marking. The flap is designed as an ellipse so the scar does not extend onto the visible lateral or medial thigh outside of the gluteal fold, being usually 27 cm transversely. Since the first profunda artery perforator (PAP) flap for breast reconstruction, we have had one patient that had an inadequate profunda artery perforator that required a transverse upper gracilis flap instead. In one case, the dominant perforator to the posterior thigh tissue was

from the descending branch of the inferior gluteal artery.

Surgical Technique

Flap harvest was initially performed in the prone position; however, recently, the technique has been modified to use a supine “frog-leg” position. The supine frog-leg position offers the advantage of decreased operative time because of rapid dissection from a medial approach and the lack of a need for repositioning. The prone position uses a lateral approach and maintains the possibility of conversion to a transverse upper gracilis flap if no adequate perforators are identified (in our series, this has not been required). When the supine approach is used, there is no specific bailout, and therefore preoperative imaging is essential. The elliptical incision is made and dissection proceeds to the superficial fascia. Beveling in the lateral thigh can increase flap volume and potentially help with postoperative donor-site contour. Beveling should be limited superiorly to avoid disturbing the contour of the inferior buttock and gluteal fold. In the prone approach, dissection proceeds laterally to the muscular fascia and the flap is elevated in a suprafascial plane. Dissection proceeds relatively rapidly until near the marked perforator and the fascia is entered. Subfascial dissection helps with perforator identification. In the supine position, the fascia is entered over the gracilis muscle and the vascular pedicle is identified approximately 3 cm posterior to the gracilis muscle. Once the key perforator is identified, standard perforator dissection pro-



Video. Video, Supplemental Digital Content 1, demonstrates the profunda artery perforator flap procedure in the prone position, <http://links.lww.com/PRS/A426>.

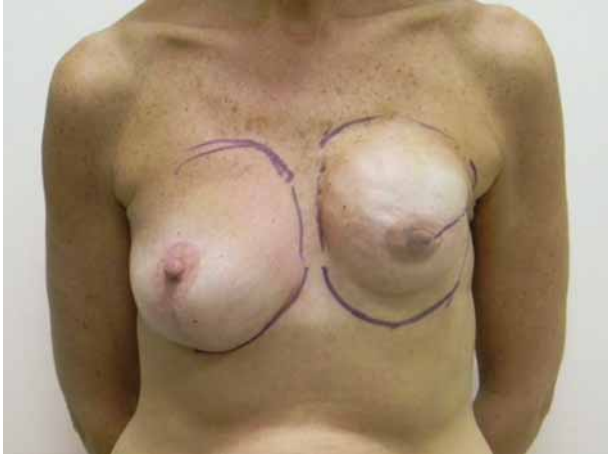

Fig. 1. Case 1. A 50-year-old woman is shown following unilateral failed implant reconstruction.

ceeds to harvest the desired pedicle length and vessel diameter. The donor site is closed in a multilayer fashion over a drain. After recipient-site preparation, the anastomosis is performed. The flap is deepithelialized and inset. (See Video, Supplemental Digital Content 1, which demonstrates the profunda artery perforator flap procedure, <http://links.lww.com/PRS/A426>.) In the supine or prone position, a profunda artery perforator flap can be raised in approximately 80 minutes.

Postoperative Care

Standard postoperative free flap care and monitoring is performed. The patient can ambulate on postoperative day 1, but should avoid any strenuous exercise for 4 weeks. Length of hospital stay has been 2 to 4 days.

CASE REPORTS

Case 1

A 50-year-old woman with a history of unilateral total mastectomy with two-stage tissue expander and implant reconstruction

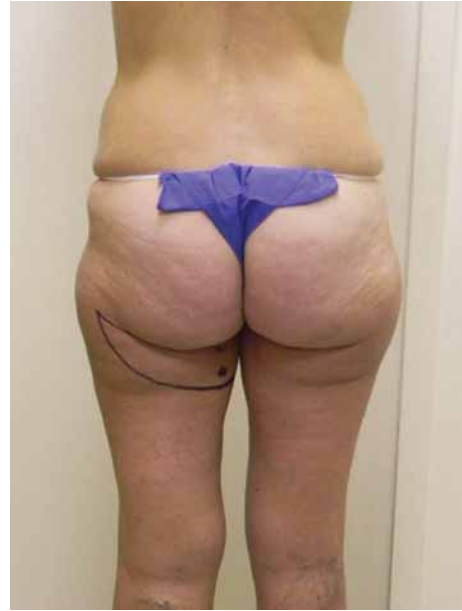

Fig. 3. Case 1. The skin perforators were identified and marked and a skin paddle measuring 24 × 7 cm was designed.

tion 4 years previously presented for implant removal and autologous reconstruction secondary to capsular contracture (Fig. 1). After preoperative imaging (Fig. 2), an elliptical skin paddle (24 × 7 cm) was designed (Fig. 3). She underwent removal of a 300-cc silicone implant and reconstruction with a 365-g profunda artery perforator flap from the prone position (Fig. 4, above and center). (See Video, Supplemental Digital Content 1, which demonstrates the profunda artery perforator flap procedure, <http://links.lww.com/PRS/A426>.) The pedicle was 10 cm in length, with a 2.2-mm artery and a 3.0-mm vein. After the vascular anastomoses to the internal mammary vessels, the flap was deepithelialized and inset (Fig. 4, below). The patient was discharged from the hospital on the second postoperative day and experienced no postoperative complications. The patient is shown at 4 months after reconstruction (Figs. 5 and 6).

Case 2

A 45-year-old woman underwent bilateral nipple-sparing mastectomies and, secondary to lack of abdominal tissue (body

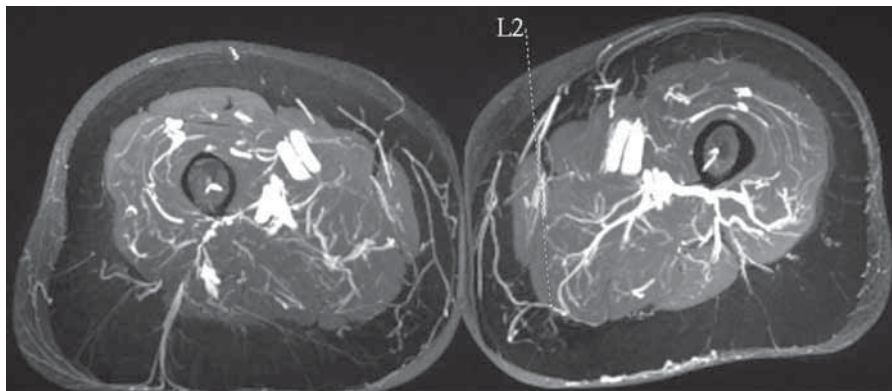


Fig. 2. Case 1. Magnetic resonance angiography was performed to identify posterior thigh profunda femoris perforators.

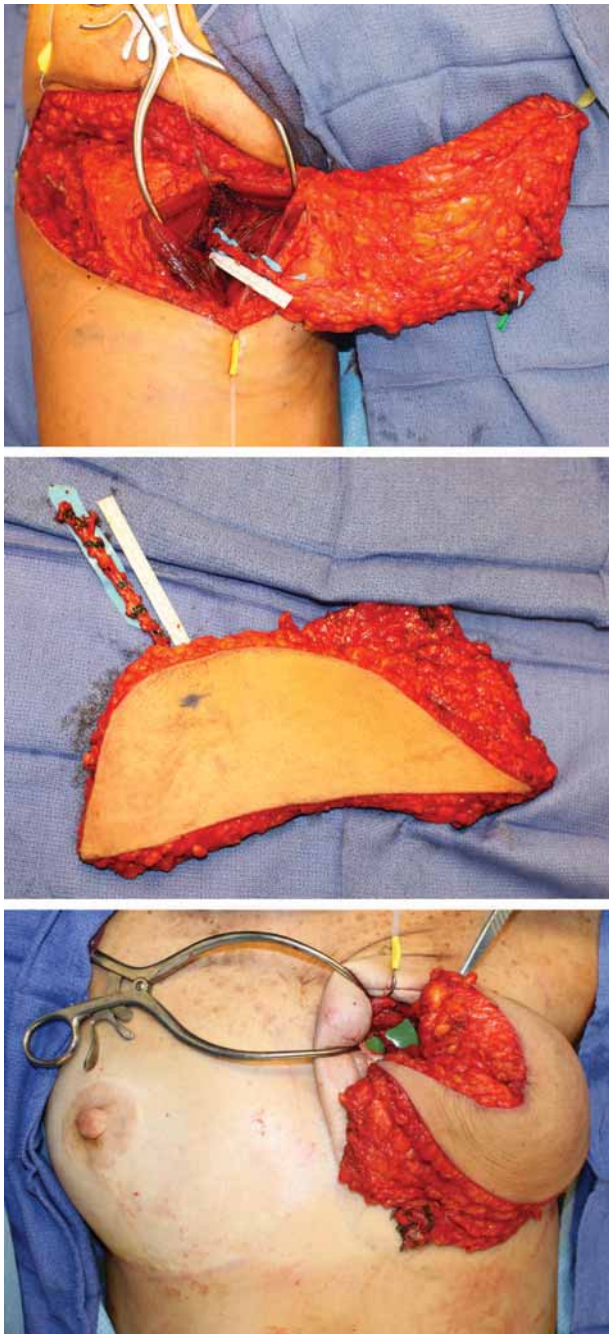


Fig. 4. Case 1. (Above) The flap was harvested from the prone position. (Center) The profunda artery perforator flap provided 365 g of tissue in a long elliptical shape. The vascular pedicle was approximately 10 cm in length. (Below) The profunda artery perforator flap provides the ideal shape for coning of transferred tissue to form a natural appearing breast.

mass index, 18.2), bilateral profunda artery perforator flap reconstruction. The supine approach was used (Fig. 7). Mastectomy specimens were approximately 280 g each, and both flaps were approximately 400 g. The patient was discharged to home on postoperative day 3 without complication. The patient is shown at 7 weeks after reconstruction (Fig. 8).

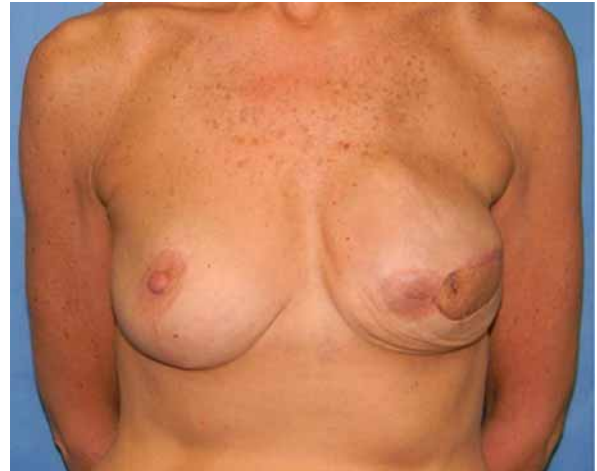

Fig. 5. Case 1. Postoperative view of the patient at 4 months after breast reconstruction with a profunda artery perforator flap before nipple reconstruction and skin island removal.

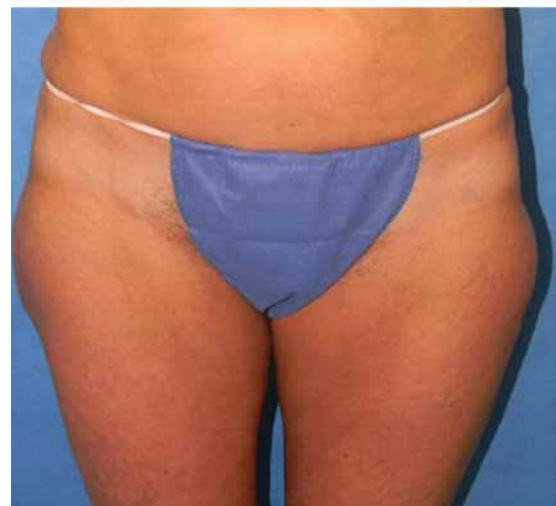
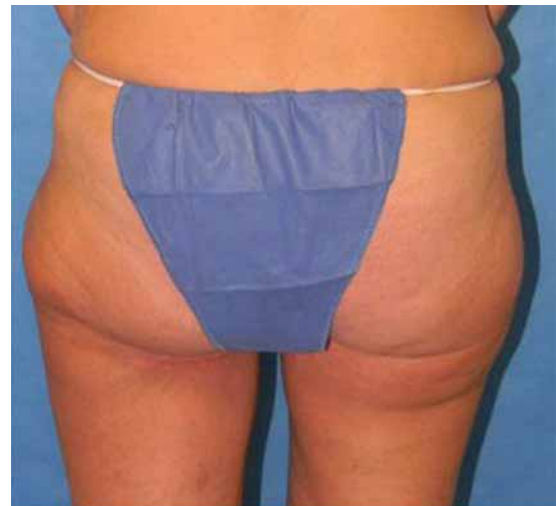
Fig. 6. Case 1. (Above) Posterior and (below) anterior views of the donor site 4 months postoperatively.

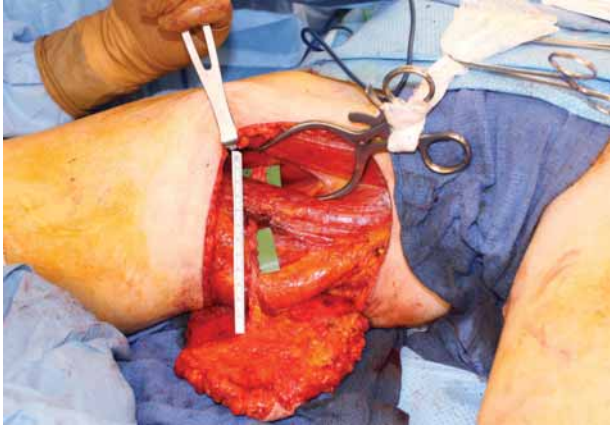


Fig. 7. Case 2. Profunda artery perforator flap harvest from the supine position.

Case 3

A 51-year-old woman underwent bilateral nipple-sparing mastectomies and bilateral profunda artery perforator flap reconstruction. Mastectomy specimens weighed 172 and 196 g, and the flaps weighed 270 and 334 g. The patient was discharged to home on postoperative day 3 without complication. The patient is shown at 7 weeks after reconstruction (Fig. 9).

Case 4

A 38-year-old woman underwent bilateral breast reconstruction with the profunda artery perforator flap following bilateral mastectomies and failed implant reconstruction. The flap weights were 334 and 262 g. The patient had significant pectus excavatum on the right and therefore the larger flap was used on this side. The patient was discharged on postoperative day 3 without complication. The patient is shown preoperatively and at 3 months following reconstruction (Figs. 10 and 11).

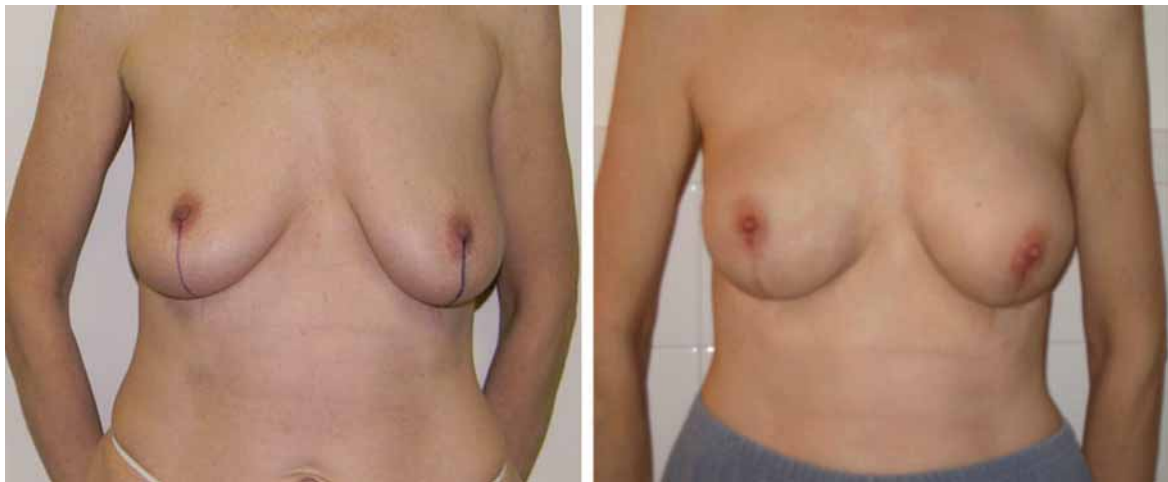


Fig. 8. Case 2. (Left) Preoperative and (right) 7-week postoperative views of the patient after bilateral breast reconstruction following bilateral nipple-sparing mastectomies.

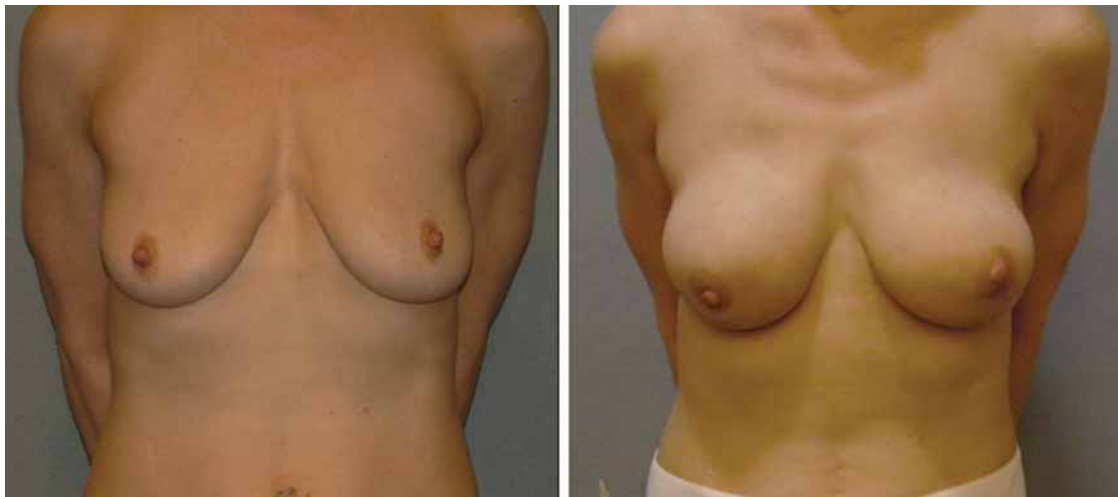


Fig. 9. Case 3. (Left) Preoperative and (right) 7-week postoperative views of the patient after bilateral breast reconstruction following bilateral nipple-sparing mastectomies.

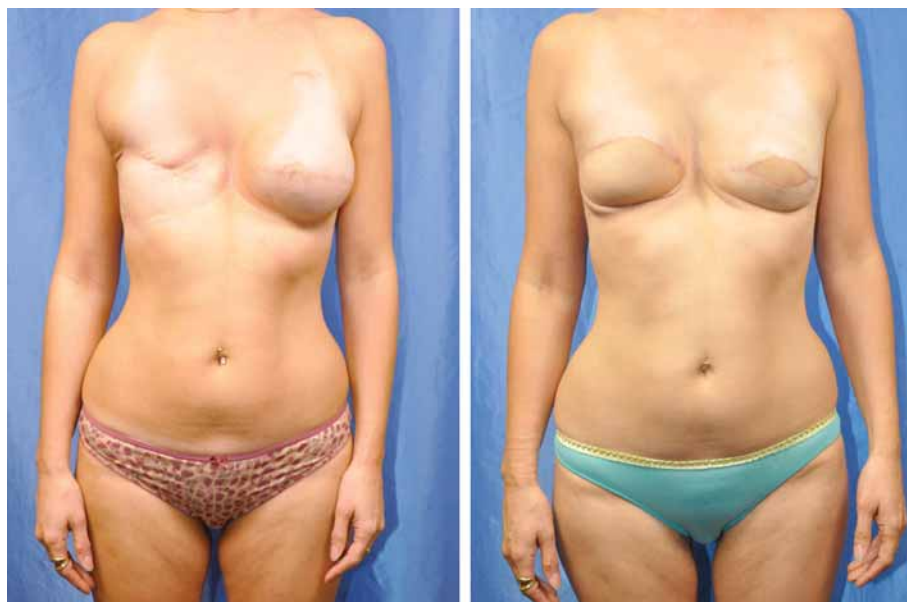

Fig. 10. Case 4. (Left) Preoperative and (right) 3-month postoperative views of the patient after bilateral breast reconstruction following bilateral mastectomies.

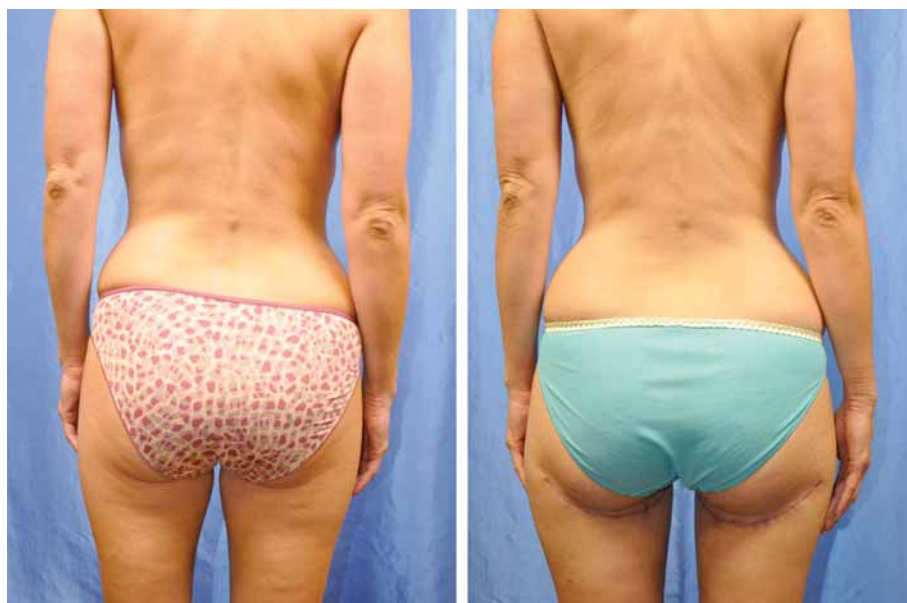

Fig. 11. Case 4. (Left) Preoperative and (right) 3-month postoperative views showing profunda artery perforator flap donor sites.

RESULTS

All profunda artery perforator flaps were successful. In two flaps, there was less than 10 percent fat necrosis. There have been two donor-site complications: one seroma and one hematoma.

Advantages

In many women, the posterior thigh is a potential donor site. The pedicle length, as long as

13 cm (average, 9.9 cm), provides versatility at the recipient site. The flap can be used for either ipsilateral or contralateral breast reconstruction, and either the internal mammary or thoracodorsal vessels can be used. In our series, only the internal mammary vessels have been used. The vessels have been of adequate size to provide for a good size match with the internal mammary vessels (average artery size, 2.2 cm; average vein

size, 2.8 cm). All veins have been of sufficient size to allow use of a venous coupler (Tables 1 and 2).

The elliptical design provides an ideal shape for coning to create a natural breast. Unlike gluteal flaps, the profunda artery perforator flap does not affect buttock contour. The posterior thigh tissue is more malleable than abdominal and gluteal tissue, allowing for better three-dimensional shaping of the breast. We have routinely been able

to obtain proportional flap volume to match the mastectomy flap volumes despite a wide range of height and weight. The donor site has also been well tolerated in patients with various body mass indexes. The transverse upper gracilis flap provides a similar tissue quality but has decreased volume and a shorter pedicle, sacrifices the gracilis muscle, and has a visible scar anteriorly (Table 3). The profunda artery perforator flap avoids dis-

Table 1. Recipient- and Donor-Site Size

Case	BMI (kg/m ²)	Mastectomy Weight (g)		PAP Flap Weight (g)	
		Left	Right	Left	Right
1	21.8	300-cc implant	N/A	365	N/A
2	19.9	190	230	235	275
3	25.8	700-cc implant	N/A*	346	348
4	20.7	400-cc implant	N/A*	262	334
5	23	370	N/A	311	N/A
6	27.5	N/A*	N/A	600	N/A
7	26.4	400-cc implant	N/A*	695	665
8	27.5	399	N/A*	510	560
9	18.2	280	280	400	405
10	20.2	350-cc implant	350-cc implant	330	380
11	32.1	403	417	435	427
12	22.1	172	196	334	270
13	20.4	340-cc implant	340-cc implant	345	390
14	22	126- and 350-cc implant	116- and 350-cc implant	281	302
15	21	Tissue expander	None	262	334
Average	23.2	316	326	381	391

PAP, profunda artery perforator; BMI, body mass index; N/A, not applicable.

*A permanent implant had previously been removed with no reconstruction.

Table 2. Profunda Artery Perforator Flap Skin Paddle Dimensions and Pedicle Characteristics

Flap	Flap Dimensions (cm)	Pedicle Type	Pedicle Length (cm)	Artery Diameter (mm)	Vein Diameter (mm)
1	24 × 7	Septocutaneous	10	2.2	3.0
2	24 × 7	Septocutaneous	7	1.6	3.0
3	24 × 7	Septocutaneous	8	1.5	2.5
4	24 × 7	Septocutaneous	7	2.0	2.5
5	24 × 7	Septocutaneous	7	2.0	2.5
6	32 × 7	Septocutaneous	10	2.2	3.0
7	32 × 7	Septocutaneous	10	2.2	3.0
8	24 × 7	Septocutaneous	9	2.2	3.0
9	25 × 7	Musculocutaneous	9	2.3	3.0
10	33 × 6	Septocutaneous	10	2.0	2.5
11	33 × 6	Septocutaneous	9	1.8	2.0
12	28 × 7	Septocutaneous	11	2.5	3.0
13	28 × 7	Septocutaneous	12	2.5	3.0
14	28 × 7	Septocutaneous	10	2.2	2.6
15	28 × 7	Septocutaneous	10	2.4	2.8
16	25 × 7	Septocutaneous	11	2.4	2.8
17	25 × 7	Septocutaneous	10	2.8	3.7
18	25 × 7	Septocutaneous	10	2.2	2.8
19	25 × 7	Septocutaneous	10	2.4	3.5
20	25 × 6.5	Septocutaneous	10	2.2	2.5
21	25 × 6.5	Septocutaneous	10	2.2	2.5
22	27 × 7	Septocutaneous	10	2.2	2.0
23	27 × 7	Septocutaneous	10	2.5	3.0
24	32 × 7	Musculocutaneous	13.0	2.5	2.5
25	32 × 7	Musculocutaneous	13.0	2.1	2.0
26	27 × 7	Septocutaneous	10.5	2.2	3.0
27	27 × 7	Septocutaneous	10.7	2.2	3.0
Average	27 × 7	Septocutaneous	9.9	2.2	2.8

Table 3. Comparison of the Profunda Artery Perforator Flap and the Transverse Upper Gracilis Flap

	PAP	TUG
Donor tissue	Posterior thigh fascia, subcutaneous tissue, and skin	Gracilis muscle, medial thigh, subcutaneous tissue, and skin
Pedicle	Profunda artery perforators	Medial femoral circumflex
Pedicle length, cm	7–13	6–8
Artery size, mm	2.2	1.6
Sensory nerve	Branch of posterior femoral cutaneous nerve	Branch of obturator nerve
Scar	Not visible to patient	Visible to patient
Position for harvest	Supine or prone	Supine
Lymphatic damage	Preserved	Possible to damage

PAP, profunda artery perforator; TUG, transverse upper gracilis.

section near the inguinal lymphatics and should reduce the risk of lymphedema and seroma. The posterior femoral cutaneous nerve is found in the subfascial plane in the posterior midthigh, which provides the possibility of transferring a sensitized flap with branches from this nerve.

Disadvantages

The main disadvantage of the profunda artery perforator flap is the potential need for prone positioning and intraoperative repositioning; however, as we have gained experience with this technique, we have transitioned to using a supine frog-leg approach. In addition, there may be size limitations in reconstruction for larger breasted women, although our profunda artery perforator flaps have ranged from 235 to 695 g, with an average of 385 g.

Complications

All profunda artery perforator flaps have been successful. As with all microvascular breast reconstruction, there is a risk of vascular compromise and the possibility for fat necrosis of the transferred tissue. In our series, we have had no vascular complications. We have seen less than 10 percent fat necrosis in two flaps. We have had two donor-site complications. There was one seroma, which was managed with a drain and resolved within 1 week, and one hematoma that caused a partial wound dehiscence and healed with local wound care. We have not had any other donor-site complications (e.g., significant postoperative posterior thigh sensation changes or disruptions in gait). We have noted that there is a potential to accentuate a preoperatively prominent saddlebag if the flap is not beveled to include the subcutaneous soft tissue in this area. In our series, no patients have required any secondary recontouring procedures. In addition, there is the possibility of damage to the posterior femoral cutaneous nerve in the posterior thigh. If a medial pedicle is chosen, elevation of the flap should continue in the suprafascial plane fol-

lowing perforator isolation to avoid injury to the posterior femoral cutaneous nerve. In our series, there have been no cases of neurapraxia.

CONCLUSIONS

We present a new technique for breast reconstruction with a series of 27 flaps. The profunda artery perforator (PAP) flap provides a long pedicle with sufficient vessel diameter, preserves muscle, can be optimally coned, and results in a fairly well-hidden scar and donor-site contour. In this series, there have been minimal complications and minimal amounts of fat necrosis. This is an excellent option when the abdomen is not available, and it has become our second-choice flap behind the deep inferior epigastric perforator flap.

Nicholas T. Haddock, M.D.

Department of Plastic Surgery
New York University Langone Medical Center
550 First Avenue, TCH 169
New York, N.Y. 10016
haddockmd@gmail.com

REFERENCES

- Allen RJ, Treece P. Deep inferior epigastric perforator flap for breast reconstruction. *Ann Plast Surg.* 1994;32:32–38.
- Allen RJ, Tucker C Jr. Superior gluteal artery perforator free flap for breast reconstruction. *Plast Reconstr Surg.* 1995;95:1207–1212.
- Lotempio MM, Allen RJ. Breast reconstruction with SGAP and IGAP flaps. *Plast Reconstr Surg.* 2010;126:393–401.
- Hurwitz DJ. Closure of a large defect of the pelvic cavity by an extended compound myocutaneous flap based on the inferior gluteal artery. *Br J Plast Surg.* 1980;33:256–261.
- Angrigiani C, Grilli D, Thorne CH. The adductor flap: A new method for transferring posterior and medial thigh skin. *Plast Reconstr Surg.* 2001;107:1725–1731.
- Song YG, Chen GZ, Song YL. The free thigh flap: A new free flap concept based on the septocutaneous artery. *Br J Plast Surg.* 1984;37:149–159.
- Ahmadzadeh R, Bergeron L, Tang M, Geddes CR, Morris SF. The posterior thigh perforator flap or profunda femoris artery perforator flap. *Plast Reconstr Surg.* 2007;119:194–200; discussion 201–202.
- Paletta C, Bartell T, Shehadi S. Applications of the posterior thigh flap. *Ann Plast Surg.* 1993;30:41–47.